Pathology of Chronic Hypersensitivity Pneumonitis

What Is It? What Are the Diagnostic Criteria? Why Do We Care?

Andrew Churg, MD; AnaMaria Bilawich, MD; Joanne L. Wright, MD

• ***Context.***—**Chronic hypersensitivity pneumonitis (CHP) has emerged from obscurity during the past 15 years and is now recognized as a very common form of fibrosing interstitial pneumonia but one that is frequently misdiagnosed both clinically and on surgical lung biopsy as usual interstitial pneumonia/idiopathic pulmonary fibrosis (UIP/IPF) or fibrotic nonspecific interstitial pneumonia.**

Objective.—**To review the pathologic features of CHP.**

Data Sources.—**Clinical, pathology, and radiology literature were used.**

Conclusions.—**Upper lobe–predominant fibrosis and/or air-trapping on computed tomography scan are features of CHP but not UIP/IPF; however, radiologic separation is possible in only about 50% of cases. Morphologically, CHP sometimes mimics UIP/IPF, but CHP often shows isolated foci of peribronchiolar (centrilobular) fibrosis, frequently associated with fibroblast foci, and in CHP, fibrosis may bridge from the centrilobular region to another bronchiole, an interlobular septum, or the pleura ("bridging fibrosis"). This set of findings is uncommon in UIP/IPF. In addition, CHP may produce a picture of fibrotic nonspecific interstitial pneumonia. Although giant cells/granulomas are usually present in subacute hypersensitivity pneumonitis, they are much less frequently found in CHP, and their absence does not contradict the diagnosis. This diagnostic separation is clinically important because CHP is treated differently than UIP/IPF is (immunosuppressive agents versus antifibrotic agents); further, there are some data to suggest that removing the patient from antigen exposure improves outcome, and there is evidence that patients with CHP have a much better survival prognosis after lung transplantation than do patients with UIP/IPF. In most cases, accurate diagnosis of CHP requires consultation among clinicians, radiologists, and pathologists.**

(*Arch Pathol Lab Med.* 2018;142:109–119; doi: 10.5858/arpa.2017-0173-RA)

Many pathologists have never heard of chronic hypersensitivity pneumonitis (CHP), but in the past 15 years, CHP has emerged as an important problem in fibrosing interstitial pneumonias, a problem that encompasses definitions of clinical, radiologic, and pathologic features required for the diagnosis and issues of treatment and prognosis (for a recent short review of clinical features and imaging see Salisbury et al).[1]

In current practice, whether a patient has CHP is a common, multidisciplinary discussion, and one about which there is often considerable disagreement. In a formal study, Walsh et al[2] asked 7 experienced multidisciplinary discussion groups, comprising clinicians, radiologists, and pathologists, to review the same 70 cases and examined the level of agreement. The intergroup weighted κ coefficient for a diagnosis of idiopathic pulmonary fibrosis (usual interstitial pneumonia/idiopathic pulmonary fibrosis [UIP/IPF]; the designation UIP/IPF is used here to distinguish it from CHP with a UIP-like pattern) was 0.71, for a diagnosis of connective tissue disease–associated interstitial lung disease 0.73, but, for CHP, was only 0.29. Some (unknown) proportion of cases that once would have been labeled UIP/IPF are now viewed as CHP. Ohtani et al[3] described 8 of 17 patients (47%) with bird exposure ultimately diagnosed as CHP who were initially thought to have UIP/IPF, and Morell et al[4] reported that 20 of 46 patients (43%) initially believed to have IPF on the basis of the American Thoracic Society 2011 criteria[5] turned out to have CHP on more detailed evaluation. This problem is becoming more frequent in diagnostic pathology practice because the current recommendation is that patients with clinically and radiologically typical UIP/IPF do not need a surgical lung biopsy,[5] so that the relative number of UIP/IPF biopsies is decreasing. However, judging from consultation cases, UIP/IPF is being overdiagnosed by pathologists with considerable frequency, and it is clear, on review, that many cases so labeled are actually CHP with a UIP-like pattern.

In the past, this distinction was probably moot because the basic approach to all fibrosing interstitial pneumonias was to treat them with steroids. However, in the current era, separation of UIP/IPF from CHP is crucial because the former is treated with antifibrotic agents (pirfenidone, nintedanib),[6] whereas CHP is treated with immunosuppressive agents.[7] The general definition of hypersensitivity

Accepted for publication April 18, 2017.

Published as an Early Online Release May 24, 2017.

From the Departments of Pathology (Dr Churg) and Radiology (Dr Bilawich), Vancouver General Hospital and University of British Columbia, Vancouver, Canada; and the Department of Pathology (Dr Wright), St Paul's Hospital and University of British Columbia, Vancouver.

The authors have no relevant financial interest in the products or companies described in this article.

Reprints: Andrew Churg, MD, Department of Pathology, Vancouver General Hospital, JPPN 1401, 910 W 10th Ave, Vancouver, BC V5Z 1M9, Canada (email: achurg@mail.ubc.ca).

Downloaded from https://aplm.kglmeridian.com at 2026-03-06 via free access

pneumonitis (HP) includes exposure to a sensitizing antigen (sometimes called an inciting agent in the literature), and there is some evidence that removing a patient with CHP from antigen exposure improves survival,[8] although other reports deny that,[9,10] so correct diagnosis of CHP cases may be important to alert the clinician to look for a source of exposure. Patients with CHP have a considerably better prognosis after lung transplantation than do patients with UIP/IPF, apparently because patients with CHP are less susceptible to bronchiolitis obliterans.[11] All these issues mandate an accurate diagnosis of CHP versus some other form of fibrosing interstitial pneumonia.

A major part of the problem in recognizing CHP is that many of these patients (at least 50% but probably more[1]) have a fibrotic lung disease without a recognizable antigen exposure. Detection of circulating immunoglobulin G against specific antigens may or may not reveal the sensitizing agent, and the same is true of inhalation-challenge testing, which is performed in only a few laboratories and which may not produce a physiologic reaction in CHP. In this circumstance, imaging and pathologic features become crucial to establishing the diagnosis, but radiologic separation of CHP from UIP/IPF or fibrotic nonspecific interstitial pneumonia (NSIP) has been estimated to be feasible in no more than 50% of cases,[12] so that the diagnosis in a significant proportion of cases will fall to the pathologist. However, the pathology literature on CHP is fairly scanty, the overall number of cases described is small, and even within those cases, there is controversy about the exact features that allow a diagnosis of CHP.

This brief review will attempt to summarize the pathology literature regarding CHP, highlight the outstanding questions, and provide pathologists with some guidelines for the diagnosis.

DEFINITION OF CHP

In a broad sense, the literature classifies HP into acute, subacute, and chronic forms, but the exact definition for each of those categories, especially for CHP, is contentious. There are basically 2 views: one is that CHP is defined by time since the appearance of symptoms (variously described in the literature as greater than 3 months, 4 months, or 1 year) and/or the pattern of disease presentation ("recurrent," "insidious," versus "acute"); the other is that CHP is defined only by the presence of fibrosis either on imaging or from biopsy (reviewed in Salisbury et al[1] and Spagnolo et al[13]). In our view, the evidence is clear (see Relationship of Pathologic Findings in CHP to Prognosis below) that the presence of fibrosis is associated with a considerably worse prognosis compared with patients with HP who do not have fibrosis (under this definition, the latter are labeled as having *acute* or *subacute* CHP, depending on presentation), and we will use *CHP* here to indicate only HP cases with fibrosis. Arguments about time course/patterns of presentation are beyond the scope of this review, but the interested reader is referred to Ohtani et al,[3] Spagnolo et al,[13] and Lacasse et al.[14]

IMAGING FEATURES OF CHP

Characteristic findings on high-resolution computed tomography (CT) chest scans in patients with CHP include fibrosis with reticulation, architectural distortion, traction bronchiectasis, and bronchiolectasis (Figure 1, A through D). Honeycombing, which is a requirement for a diagnosis of UIP/IPF, has been reported in 16% to 69% of CHP cases,[12,15,16] and in contrast to the honeycombing in patients with UIP/IPF, honeycombing in patients with CHP seldom has a basal predominance. The reticulation in CHP can be patchy, random or peribronchovascular or have a predominantly subpleural distribution, mimicking UIP/IPF. Fibrosis may be predominantly mid or upper zonal with basal sparing (Figure 1, A through D) but is often predominantly in the lower zone and is sometimes evenly distributed.[12,15,17,18] Commonly, superimposed findings of subacute HP are encountered, including patchy ground-glass opacities usually affecting less than 50% of the lung parenchyma. Lobular areas of decreased attenuation and vascularity (Figure 1, E and F) are described in approximately 80% of patients, with poorly defined centrilobular nodules in approximately 50% of patients.[12,16–21]

In contrast, UIP/IPF shows reticulation in all lobes; no or minimal ground-glass opacities; honeycombing, which is often extensive; and a peripheral and basal distribution.[12] However, as noted, these criteria fail to provide separation in 50% of cases; in particular, there can be considerable overlap between CHP and UIP/IPF.

PATHOLOGIC FEATURES OF CHP

There are relatively few articles that describe the pathologic features of CHP, and comparisons among those studies are bedeviled by the few cases, slightly differing definitions of the various patterns observed, and variable information about each particular feature. Some articles only provide pathologic diagnoses without any diagnostic criteria. For the most part, we cite articles that have enough pathologic detail to be sure about what is meant or to indicate that use standard definitions.

Subacute HP

By our stated definition, interstitial fibrosis must be present to make a diagnosis of CHP, but areas of traditional subacute HP may be present as well, and those findings are very helpful in arriving at the correct diagnosis. Typical subacute HP appears as peribronchiolar (centrilobular) interstitial, chronic inflammatory infiltrates of lymphocytes, plasma cells, and sometimes a few eosinophils (for a review see, Churg and Muller[22] and Herbst and Myers[23]). Subacute HPs have associated nonnecrotizing granulomas or giant cells in perhaps 70% of cases; the granulomas or giant cells are usually described as *interstitial*, but airspace giant cells and granulomas can also be found.[24] "Bronchiolitis" is often reported in subacute HP, but what that really means is that the chronic inflammatory infiltrate is present in the wall of the bronchioles as well as in the alveolar interstitium (and rarely present only in the bronchiolar walls and not in the interstitium). Small foci of organizing pneumonia (such as bronchiolitis obliterans organizing pneumonia and cryptogenic organizing pneumonia) may also be present but have little specificity. Less commonly, subacute HP manifests as a pattern of cellular NSIP, with or without giant cells and granulomas.

The exact frequency with which areas of subacute HP are seen in CHP is unclear. Churg et al[25] described subacute HP areas in 7 of 13 CHP cases (54%). Takemura et al[26] reported bronchiolitis in 22 of 22 cases (100%) of CHP with a UIP pattern (it is not clear from that article whether those cases also had peribronchiolar interstitial inflammation). In a later article, Churg et al[27] found areas of subacute HP in 12 of 18 CHP biopsies (67%) with a UIP-pattern. Chiba et al[28] reported bronchiolitis in 7 of 16 cases (44%) with a UIP-

Downloaded from https://aplm.kglmeridian.com at 2026-03-06 via free access

Table 1. Frequency of Pathologic Findings in Chronic Hypersensitivity Pneumonitis					
Source, y	Isolated Peribronchiolar Fibrosis, No. (%)	Peribronchiolar Fibrosis With Another Pattern of Fibrosis, No. (%)	Bridging Fibrosis, No. (%)	UIP-like Fibrosis, No. (%)	NSIP-like Fibrosis, No. (%)
Akashi et al,[31] 2009; n = 16	NR	16 (100)	8 (50)	7 (44)	NR
Chiba et al,[28] 2016; n = 16	NR	14 (87)	11 (69)	16 (100)	NR
Churg et al,[27] 2009; n = 25	3 (12)	15 (60)	15 (60)	18 (72)	4 (16)
Churg et al,[25] 2006; n = 13	NR	3 (23)	Present	9 (69)	4 (31)
Takemura et al,[26] 2012; n = 22	NR	22 (100)	8 (36)	22 (100)	NR
Wang et al,[32] 2017; n = 39	10 (26)	7 (18)	NR	7 (18)	22 (56)

Abbreviations: NR, not specifically reported; NSIP, nonspecific interstitial pneumonia; UIP, usual interstitial pneumonia.

pattern, and Myers[29] stated that bronchiolitis is "universal" in HP cases.

Chronic HP: Peribronchiolar Fibrosis, Bridging Fibrosis, and UIP-like Fibrosis

Table 1 lists the various individual pathologic components and the frequency of each component, as reported in the literature, restricting the analysis to reports with pathologic details. Much of that information is derived from patients with bird exposures, but whether the mixture of those components varies with the specific antigen is not known. Using the definition we are following here, some pattern of fibrosis is always present in CHP and may be broadly divided into purely peribronchiolar (centrilobular) fibrosis, bridging fibrosis (defined below), peripheral lobular/subpleural fibrosis with or without centrilobular or bridging fibrosis, and fibrotic NSIP-like fibrosis (there are other distinctive, airway-centered morphologic entities that may represent CHP; these are discussed in Other Possible Morphologic Variants of CHP below.

The fibrosis in CHP may be predominantly upper zonal (Figure 1, A through D); for example, in the report by Takemura et al,[30] 7 of 17 autopsy cases (41%) of CHP demonstrated an upper zonal distribution, but Akashi et al[31] found only 1 of 16 cases (6%) with upper lobe predominance. Predominantly, upper zonal fibrosis is useful in distinguishing CHP from UIP/IPF, which should always be predominantly lower zonal. However, many cases of CHP show a lower zonal distribution.

Centrilobular/peribronchiolar fibrosis consists of fibrosis that spreads through the interstitium adjacent to, and extending away from, the bronchioles (Figures 2, A; 3; and 4, A). The fibrosis can follow alveolar walls or form blocks of fibrous tissue around the bronchioles. Peribronchiolar fibrosis may be the only fibrotic lesion in a given CHP case (Figure 4, A), but it is commonly seen with bridging fibrosis or a UIP-like pattern (Figures 2, A and C, and 3). In CHP, peribronchiolar fibrosis is frequently associated with fibroblast foci[25–27,30] (Figures 2, B, and 4, B); and it has been suggested that this is a useful point of distinction from UIP/IPF, which uncommonly shows peribronchiolar fibrosis, and when present, the peribronchiolar fibrosis typically does not have associated fibroblast foci.[26,30]

Bridging fibrosis is essentially a more florid form of peribronchiolar fibrosis in which fibrosis spreads in the interstitium between a bronchiole and another bronchiole or, more often, between a bronchiole and an interlobular septum or a bronchiole and an area of subpleural fibrosis (Figures 2, A, and 3). Bridging fibrosis is common in CHP

Table 2. Separation of Chronic Hypersensitivity Pneumonitis (CHP) With a Usual Interstitial Pneumonia (UIP) Pattern From UIP/Idiopathic Pulmonary Fibrosis (IPF) From Video-Assisted Thoracoscopic Surgery Biopsies		
Finding	CHP	UIP/IPF
Zonal predominance	Sometimes upper-zone predominant but can be lower-zone predominant	Always lower-zone predominant
Peribronchiolar fibrosis	Common and frequently associated with fibroblast foci	Uncommon, unless the lobule has been overrun; usually not associated with fibroblast foci
Bridging fibrosis	Common	Rare, unless fibrosis is advanced and the lobule has been overrun
Areas of subacute HP	May be present	Not present by definition
Fibroblast foci	Usually present, if peribronchiolar favors HP	Always present, should not be peribronchiolar unless the disease is very advanced and the lobule has been overrun
Subpleural fibrosis	Can be identical to UIP/IPF but often much less marked and stretches of subpleural sparing may be present	Tends to be very marked with involvement of most or all of the subpleural parenchyma; large blocks of fibrosis with microscopic honeycombing common
Giant cells and granulomas	May be present, but probably most cases do not have either one	The presence of giant cells or granulomas favors another diagnosis
Interstitial inflammation	Plasma cells, lymphocytes, and a few eosinophils common, but some cases are paucicellular	Should be paucicellular
Organizing pneumonia	Common in some series	If present, represents a superimposed process
Microscopic honeycombing	May be present, but many cases do not show honeycombing	Usually present

Abbreviation: HP, hypersensitivity pneumonitis.

Downloaded from https://aplm.kglmeridian.com at 2026-03-06 via free access

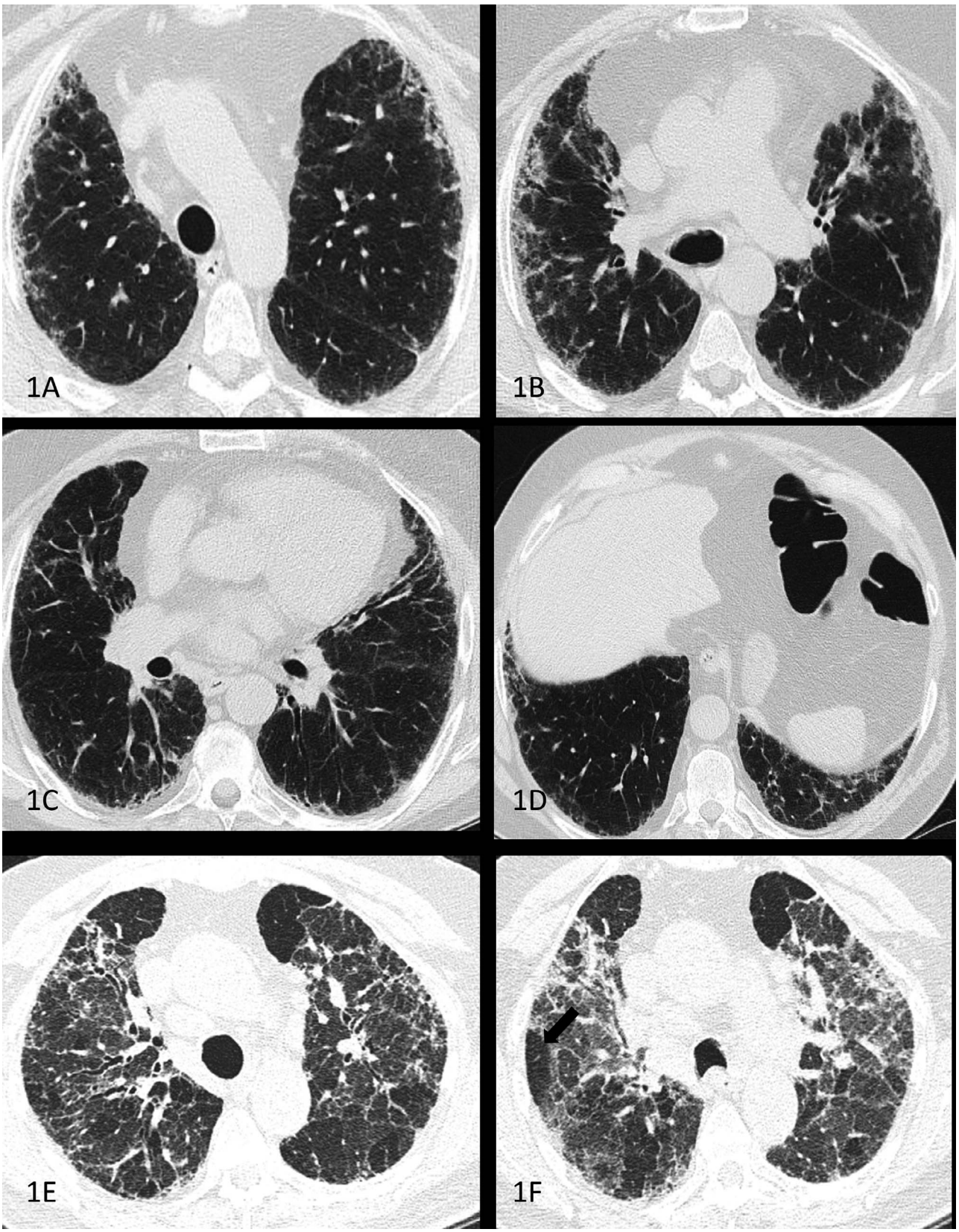

Figure 1. *Representative high-resolution computed tomography (CT) imaging of chronic hypersensitivity pneumonitis (CHP). A through D, Transverse axial CT chest images obtained through the upper (A and B), mid (C), and lower (D) lung zones demonstrate upper lung zone–predominant findings of fibrosis with reticulation, architectural distortion, and traction bronchiectasis and bronchiolectasis, in a predominantly peripheral and subpleural distribution. The biopsy findings in this case are shown in Figures 2, A through C. E and F, high-resolution CT scan of the chest through the upper lung zones of a different case obtained during inspiration (E) shows patchy peribronchovascular and peripheral reticulation with superimposed, patchy, ground-glass opacities, traction bronchiectasis and bronchiolectasis, and lobular areas of decreased attenuation.*

Downloaded from https://aplm.kglmeridian.com at 2026-03-06 via free access

(Table 2), and some authors suggest it is a prototypical lesion that is rarely seen in UIP.[26,30,31]

A UIP-like pattern, with patchy, subpleural fibrosis; fibroblast foci; and some amount of microscopic honeycombing, is also common in CHP (Figure 2, C), but often, the pattern in CHP is subtly different from UIP/IPF, with relatively less subpleural fibrosis, little to no honeycombing, and sometimes fibrosis that follows alveolar walls immediately under the pleura, rather than forming the large solid blocks of fibrosis typical of UIP/IPF (Figures 2, A, and 3). As well, the degree of peribronchiolar fibrosis or bridging fibrosis may be as severe as, or worse than, the subpleural fibrosis (Figures 2, A, and 3). However, as fibrosis gets worse in either UIP/IPF or CHP with a UIP pattern, it tends to overrun the lobule, extending to encompass bronchioles, so in advanced disease, it is sometimes impossible to separate those entities (Figure 2, C; and see Discussion).

Wang et al[32] reported that 100% of their CHP cases with a UIP pattern had fibroblast foci, and suggest that the frequency of fibroblast foci is greater in cases with a UIP pattern than in cases with only peribronchiolar fibrosis, in which they found fibroblast foci in 30%.

Some cases of CHP have very little interstitial inflammation, but other cases have a readily discernible infiltrate of lymphocytes, plasma cells, and a few eosinophils (Figure 4, B), and the numbers of inflammatory cells are greater than one would expect in UIP/IPF, which should be quite paucicellular. Lymphoid aggregates are often present in CHP; Takemura et al[26] reported lymphoid aggregates in 17 of 22 CHP cases (72%) with a UIP pattern versus 5 of 13 UIP/IPF cases (38%), and Chiba et al[28] found lymphoid aggregates in 60% of a series of 16 cases (terminology in that article is confusing because the authors appear to be using the term *follicles* for *aggregates*.). Myers[29] explicitly noted that true lymphoid follicles can be found in CHP, but in our experience, they are uncommon and raise a question of connective tissue disease–associated interstitial lung disease (ILD) when present.

Giant cells and granulomas or Schaumann bodies (which are markers of previous granulomas) are very helpful if found (Figures 3 and 4, B), but the reported proportion of cases with those features varies widely. Churg et al[27] found giant cells or granulomas in 16 of 18 cases (89%) with a UIP-like pattern and 3 of 3 cases (100%) with only peribronchiolar fibrosis, and Takemura et al[26] found giant cells in 15 of 22 cases (68%) and granulomas in 14 of 22 cases (64%). However, Chiba et al[28] described giant cells or granulomas in only 4 of 16 UIP-like cases (25%). Wang et al[32] found them in 2 of 7 UIP-like cases (28%), but in almost all cases with only peribronchiolar fibrosis. These data are somewhat difficult to interpret because, in the past, giant cells and granulomas tended to be viewed as requirements for the pathologic diagnosis of CHP, but that is no longer true, so that case-selection criteria probably changed over time.

Chronic HP: NSIP-like Fibrosis

Fibrotic NSIP (used here to denote both fibrotic NSIP and/or mixed cellular and fibrotic NSIP patterns) represents the other major pattern of interstitial fibrosis that is seen in CHP (Figure 5). Churg et al[27] reported that a fibrotic NSIP picture is less common than a UIP-like picture (4 of 25 cases [16%] versus 18 of 25 cases [72%]), but Ohtani et al[33] found about equal numbers (8 cases of fibrotic NSIP versus 11 cases UIP-like) and Wang et al[32] reported the opposite pattern (22/39 NSIP versus 7/39 UIP-like).

Many of these cases are not morphologically separable from idiopathic, fibrotic NSIP, but the presence of giant cells and granulomas or Schaumann bodies (Figure 5) favors CHP; Wang et al[32] found them in 68% of their fibrotic NSIP-pattern cases, and Churg et al[27] observed them in 100% (4 of 4) of such cases. The interstitial inflammatory infiltrate may be sparse or may be composed of lymphocytes, plasma cells, and a few eosinophils, and lymphoid aggregates with or without germinal centers may be present. In our experience, the latter finding suggests a diagnosis of connective tissue disease–associated NSIP rather than CHP.

Peribronchiolar Metaplasia

Peribronchiolar metaplasia (PBM, known in the past as *lambertosis*) refers to very fine, interstitial fibrosis that radiates outward from a bronchiole, with the fibrotic alveolar walls covered by metaplastic, ciliated bronchiolar epithelium (Figure 6). Often, but not always, the bronchiole itself shows scarring of the wall. However, PBM should be distinguished from peribronchiolar fibrosis, which typically is more coarse, may be blocklike, frequently extends much further from the airway, and does not have a covering of ciliated, metaplastic bronchiolar cells (Figures 2, A; 3; and 4, A and B).

There is some suggestion in the literature that PMB may be a marker of CHP (and that it reflects small-airway damage), but that remains to be established. Moreover, PBM can be found in otherwise healthy lungs but is particularly frequently found in lungs with any kind of fibrosing interstitial pneumonias. Fukuoka et al[34] reported PBM in 17 of 29 UIP cases (59%), 10 of 20 NSIP cases (50%), 3 of 6 desquamative interstitial pneumonia cases (50%), 9 of 18 HP cases (50%), and 2 of 18 respiratory bronchiolitis with interstitial lung disease cases (11%). Myers and colleagues[29,35] concluded that PBM was present in 50% of HP biopsies and in 100% of HP autopsies but noted that the frequency of PBM was similarly high in UIP/IPF biopsies, so that it was not diagnostically useful in that context.

Separation of UIP/IPF From CHP With a UIP-like Pattern

Separating UIP/IPF from CHP with a UIP-like pattern is by far the most difficult and contentious issue in the diagnosis of CHP and is now being recognized as a problem not only in the diagnosis of CHP but also, conversely, in UIP/IPF as well. Hashisako et al[36] circulated 20 ILD cases to 11 pathologists; the overall κ coefficient for diagnostic agreement was 0.23. Although that rose to 0.37 when diagnoses were forced into a UIP versus non-UIP dichotomy, the 2 major issues that caused dissension were the presence of interstitial inflammation away from honeycombing, a finding that might represent either CHP or connective tissue disease–associated ILD, and the presence of fibrosis around bronchioles, a frequent feature of CHP, as described above.

Most of the information on separation of UIP/IPF from CHP is derived from qualitative statements in the literature, but Akashi et al[31] and Takemura et al[26] explicitly compared

←
Expiratory high-resolution CT scan of the chest in the same patient at the same level (F) demonstrates accentuation of the areas of air trapping (eg, as indicated by the arrow).

Downloaded from https://aplm.kglmeridian.com at 2026-03-06 via free access

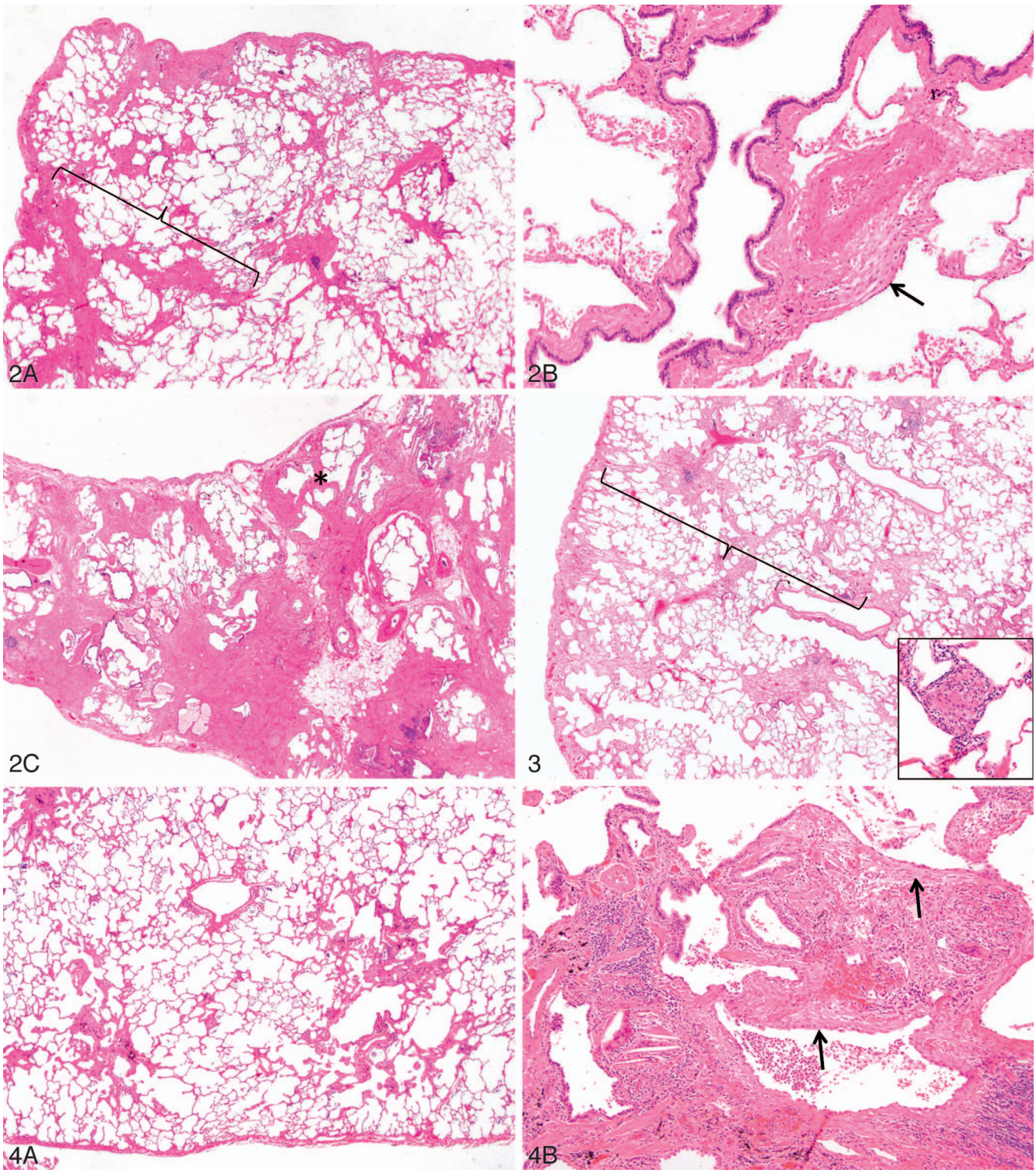

Figure 2. *Chronic hypersensitivity pneumonitis (CHP) in a patient with exposure to down bedding. A, Low-power view of the biopsy of the lower lobe of the case shown in Figure 1, A through D. There is isolated peribronchiolar fibrosis as well as bridging fibrosis (bracket indicates one bridge), with relatively little subpleural disease. This is the typical appearance of CHP. B, Higher-power view of an area of peribronchiolar fibrosis showing a fibroblast focus at the arrow; peribronchiolar fibroblast foci are a feature that favors CHP, rather than usual interstitial pneumonia/idiopathic interstitial fibrosis (UIP/IPF). C, Biopsy of the upper lobe of the same case. The picture here is indistinguishable from UIP/IPF. Asterisk (*) indicates a lobule with bridging fibrosis; however, when fibrosis is this severe, bridging becomes a nonspecific finding that no longer allows separation of UIP/IPF from CHP with a UIP pattern (hematoxylin-eosin, original magnifications ×25 [A and C] and ×200 [B]).*

Figure 3. *Chronic hypersensitivity pneumonitis in a patient with a hot tub. There is peribronchiolar fibrosis with fine fibrosis bridging to the subpleural region (bracket) as well as bronchiole to bronchiole bridging and patchy, minimal subpleural fibrosis. Inset, A granuloma in this biopsy (hematoxylin-eosin, original magnifications ×25 and ×200 [inset]).*

Downloaded from https://aplm.kglmeridian.com at 2026-03-06 via free access

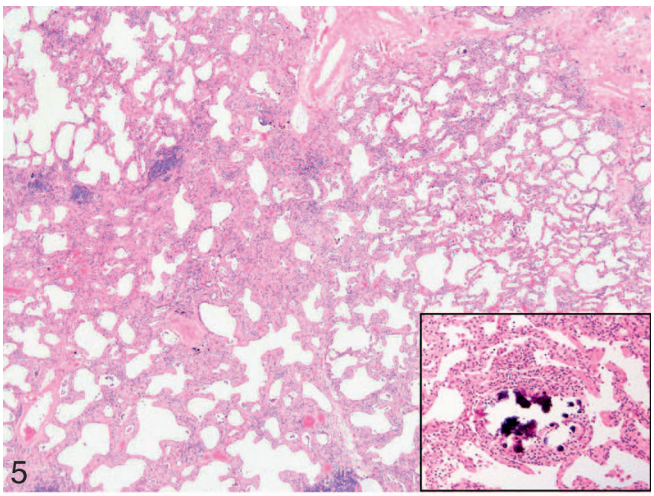

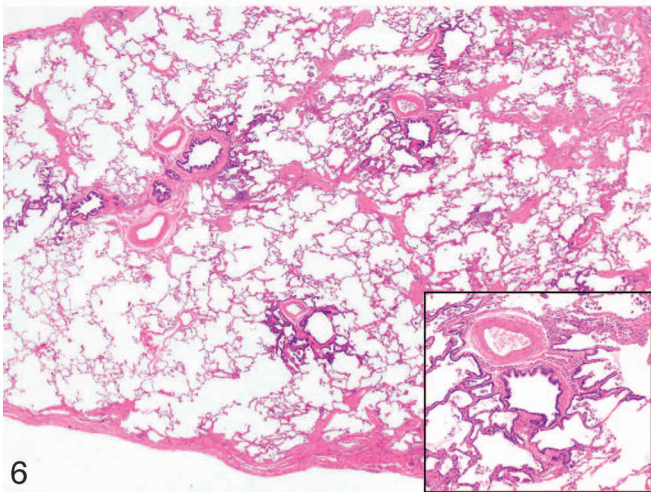

Figure 5. *Chronic hypersensitivity pneumonitis with a fibrotic, nonspecific interstitial pneumonia (NSIP) pattern in a patient with bird exposure. The biopsy shows a typical, fibrotic NSIP pattern. A Schaumann body, which is a marker of a previously present granuloma, is illustrated in the inset (hematoxylin-eosin, original magnifications ×25 and ×200 [inset]).*

Figure 6. *Chronic hypersensitivity pneumonitis (CHP) with prominent peribronchiolar metaplasia. Peribronchiolar metaplasia is present around 5 bronchioles. The inset shows the typical, extremely delicate fibrosis with overlying metaplastic bronchiolar epithelium of peribronchiolar metaplasia. Peribronchiolar metaplasia is common in biopsies of patients with CHP but is also frequent in usual interstitial pneumonia/idiopathic interstitial fibrosis cases and does not serve to separate them (hematoxylin-eosin, original magnifications ×25 and ×100 [inset]).*

CHP with a UIP-like pattern to UIP/IPF. In both studies, the features that were statistically more common in CHP/UIP were peribronchiolar fibrosis and bridging fibrosis. In the Takemura et al[26] study, bronchiolitis, organizing pneumonia, granulomas/giant cells, and "lymphocytic alveolitis with fibrosis" (which may, in fact, have been foci of subacute HP) were also more common in CHP with a UIP-like pattern. Takemura et al[26] found honeycombing in 13 of 22 cases (59%) of CHP and 10 of 13 cases (77%) of UIP, but in our experience, in CHP with a UIP-like pattern, subpleural fibrosis is often much less marked, and there can be significant stretches in which the subpleural region has minimal or no fibrosis compared with UIP/IPF (Figures 2, A, and 3).

Some studies note the presence of organizing pneumonia in cases of CHP, but care must be taken in using organizing pneumonia as a feature supporting CHP because organizing pneumonia can occasionally be found in many types of interstitial lung disease, in many instances probably representing some other, superimposed process. An acute exacerbation of a fibrotic interstitial pneumonia, which occurs in both CHP and UIP/IPF, can also look like organizing pneumonia superimposed on old fibrosis.[37]

The proportion of CHP cases that are morphologically identical to UIP/IPF is difficult to determine. Churg et al[27] noted that 2 of 18 CHP cases (11%) with a UIP-like pattern could not be separated from UIP/IPF, and Trahan et al[35] reported 2 of 15 such cases (13%) were called CHP (but their definition of *chronic* was time based, so the actual number of fibrotic cases was smaller). Ohtani et al[33] called 9 of 26 cases (35%) *UIP-like*, using pathologic definitions based on the 2002 American Thoracic Society guidelines, but whether there were morphologically atypical features for UIP/IPF was not indicated. Chiba et al[28(p1474)] described 16 cases of CHP with a UIP-like pattern, some (undefined) proportion of which had organizing pneumonia, granulomas, or lymphocytic alveolitis that "might be considered atypical of UIP" (ie, UIP/IPF). Table 2 attempts to summarize the features that favor either CHP with a UIP-like pattern or UIP/IPF.

In theory, genomic analysis might be helpful in this situation, but there is little information in this regard. Selman et al[38] found that lungs with UIP/IPF showed increased expression of genes favoring tissue remodeling, epithelial genes, and myofibroblast genes, whereas HP cases showed increased expression of genes favoring immune responses and T-cell activation. Unfortunately, it is not clear from that article whether the HP cases were subacute or chronic. Recently, Kim et al[39] described a gene expression pattern that they concluded separated UIP/IPF from a variety of other forms of interstitial lung disease, including cases of HP. Again, whether those were chronic or subacute HP cases was not indicated, and there was no specific gene expression pattern reported for the HP cases.

Other Possible Morphologic Variants of CHP: Idiopathic Bronchiolocentric Interstitial Pneumonia and Airway-Centered Interstitial Fibrosis

Yousem and Dacic[40] reported 10 cases under the name *bronchiolocentric interstitial pneumonia*. All the cases showed a pattern of bronchiolar scarring with interstitial fibrosis following the alveolar walls and covered by metaplastic bronchiolar epithelium radiating away from the bronchioles. Granulomas and giant cells were not found. The picture was somewhat similar to that of PBM, but the fibrosis was considerably more marked and more extensive, sometimes reaching to the pleura. No CT imaging data were available.

←

Figure 4. *Chronic hypersensitivity pneumonitis in a patient exposed to metal-working fluid. A, Low-power view showing patches of isolated peribronchiolar fibrosis. Note the essentially normal subpleural region. B, High-power view of an area of peribronchiolar fibrosis showing 2 fibroblast foci (arrows), individual giant cells, and moderate, chronic interstitial inflammatory infiltrate (hematoxylin-eosin, original magnifications ×25 [A] and ×200 [B]).*

Downloaded from https://aplm.kglmeridian.com at 2026-03-06 via free access

In contrast to isolated PBM, which generally appears to be innocuous,[34] 3 of 9 patients (33%) with bronchiolocentric interstitial pneumonia and follow-up died of disease, and 5 others were alive with progressive disease. Yousem and Dacic[40] speculated that this process might be a form of CHP, but none of the cases had any obvious antigen exposures.

Churg et al[41] described 12 patients with a process termed *airway-centered interstitial fibrosis*. Those cases were somewhat similar to those of Yousem and Dacic,[40] with fine interstitial fibrosis covered by metaplastic bronchiolar epithelium, again often extending to the pleura, but tending to have more peribronchiolar fibrosis, sometimes in a blocky fashion. The CT imaging showed extensive periairway fibrosis and some interstitial fibrosis. Detailed exposure histories were available for all patients, and none had a history of exposure to a known agent of HP. However, Fenton et al[42] reported a case of airway-centered interstitial fibrosis in a patient with ground-glass centrilobular nodules, exposure to birds, and precipitating antibodies against feathers (Figure 7, A and B), and Gaxiola et al[43] reported 3 such patients with pigeon exposure. Kuranishi et al[44] described 68 patients with what they also called *airway-centered interstitial fibrosis*, but the sparse illustrations suggest that the process was more concentrated as blocks of fibrosis encompassing bronchioles rather than spreading away from bronchioles in the fashion described by Yousem and Dacic[40] and Churg et al.[41] Nonetheless, 29 of the Kuranishi et al[44] cases (43%) were thought to have HP; another group had aspiration pneumonia. These data suggest that at least some cases of idiopathic bronchiolocentric interstitial pneumonia and airway-centered interstitial fibrosis are forms of CHP.

Other Differential Diagnoses

Microaspiration can cause lesions localized to membranous and particularly respiratory bronchioles and can mimic CHP with a purely peribronchiolar pattern. Often the bronchiolar walls in microaspiration are inflamed or scarred, and the process may extend a little way from the airway (Figure 8). Microaspiration may also cause the formation of small granulomas and/or giant cells in the bronchiolar walls or lumens. However, often in microaspiration, the giant cells are large and may be somewhat bizarre in the fashion commonly seen in foreign-body granulomas. The finding of aspirated material confirms the diagnosis (Figure 8), but aspirated material is not visible in every case. Digested periodic acid–Schiff stains and examination under polarized light can also be helpful in highlighting aspirated particles, particularly vegetable particles or drug tablet fillers. There are arguments in the literature about whether chronic microaspiration can lead to diffuse interstitial fibrosis, but at this point, that theory is purely conjecture, and a biopsy showing peribronchiolar fibrosis with bridging or a UIP-like pattern with peribronchiolar fibrosis is probably not caused by microaspiration.

Imaging can be very helpful when this issue arises because chronic microaspiration tends to lead to bronchiolitis visible on high-resolution CT as multilobar, centrilobular nodules or have a trees-in-bud appearance.[45,46]

Connective tissue disease–associated ILD often shares morphologic features with CHP, occasionally including peribronchiolar fibrosis and peripheral lobular fibrosis. In our experience, many lymphoid aggregates and/or lymphoid aggregates with germinal centers and a high proportion of plasma cells in the interstitial inflammatory infiltrate suggest

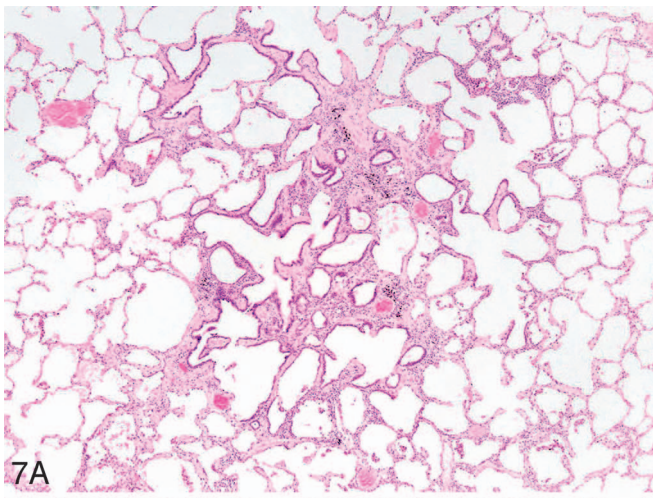

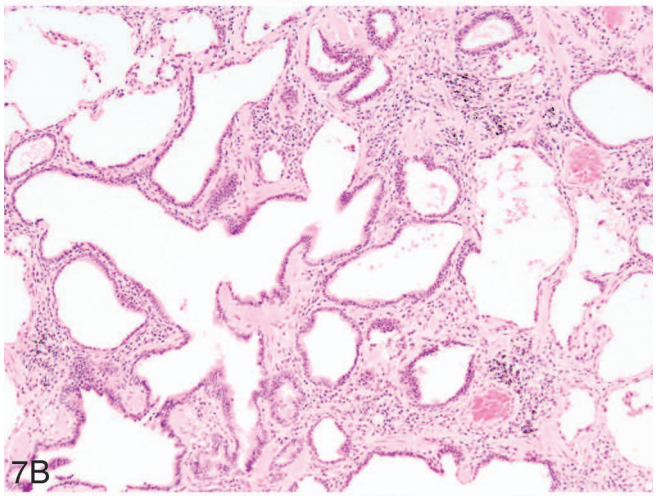

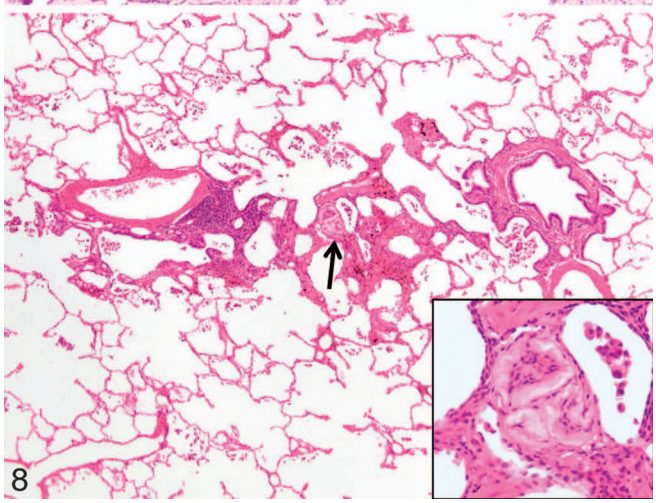

Figure 7. *Bronchiolocentric interstitial pneumonia/airway-centered interstitial fibrosis pattern of chronic hypersensitivity pneumonitis in a patient with farm and bird exposure. A, Peribronchiolar fibrosis is present and extends (as fairly fine fibrosis) a considerable distance from the bronchiole. The fibrosis is overlain by metaplastic bronchiolar epithelium, producing what looks like an exaggerated form of peribronchiolar metaplasia. B, Higher-power view showing the combination of fine, interstitial fibrosis and metaplastic bronchiolar epithelium (hematoxylin-eosin, original magnifications ×50 [A] and ×100 [B]).*

Figure 8. *Microaspiration producing peribronchiolar fibrosis. This image mimics one of the patterns of peribronchiolar fibrosis often seen in chronic hypersensitivity pneumonitis. Note the aspirated vegetable particles at the arrow and in the inset (hematoxylin-eosin, original magnifications ×25 and ×200 [inset]).*

Downloaded from https://aplm.kglmeridian.com at 2026-03-06 via free access

Table 3. Median Survival in Chronic Hypersensitivity Pneumonitis (CHP) Cases by Pathologic Pattern				
Source, y	Peribronchiolar Fibrosis–Only Survival, mo	UIP Pattern Survival, mo	Fibrotic NSIP Pattern Survival, mo	Comment
Wang et al,[32] 2017	60	40	108	Mixed exposures
Churg et al,[27] 2009	144	36	36	Mixed exposures
Gaxiola et al,[43] 2011	NA	40	NA	Bird exposures
Ohtani et al,[33] 2005	NA	50	50	Bird exposures
Takemura et al,[26] 2012	NA	80% survival at 100	NA	Mixed exposures UIP comparison group median survival 100
Chiba et al,[28] 2016	NA	27 (if >2.2 fibroblast foci/cm^2) 70% (survival at 100 if <2.2 fibroblast foci/cm^2)	NA	Bird exposures
Nunes et al,[51] 2015	NA	NA	50	Patients with CHP had considerably worse survival rates than did patients who had connective tissue disease or idiopathic NSIP

Abbreviations: NA, not applicable or not reported; NSIP, nonspecific interstitial pneumonia; UIP, usual interstitial pneumonia.

a diagnosis of a connective tissue disease–associated ILD, whereas peribronchiolar metaplasia is much more common in CHP. Clinical information is again crucial; overt connective tissue disease or convincing positive connective tissue disease serology favors a diagnosis of connective tissue disease–associated ILD.

RELATIONSHIP OF PATHOLOGIC FINDINGS IN CHP TO PROGNOSIS

Imaging studies (for example[10]) show clearly that the prognosis of HP with fibrosis, ie, CHP as used here, is considerably worse than the prognosis of HP without fibrosis, ie, subacute HP, and Walsh et al[47] showed that the severity of fibrosis on high-resolution CT in CHP was a much better indicator of prognosis than were physiologic measurements. Vourlekis et al[9] found that patients whose biopsies showed any (defined simply as >5% fibrosis or honeycombing) did worse than those with no fibrosis. Using more modern definitions of pathologic patterns, Ohtani et al,[33] Churg et al,[27] and Wang et al[32] all concluded that patients with HP and any pathologic pattern of fibrosis (ie, CHP as used here) fare considerably worse than those without fibrosis (ie, subacute HP as used here).

A question of interest is whether specific patterns of fibrosis in CHP correlate with survival or time to transplantation, and on that, only limited data exist, some of which is contradictory. Table 3 summarizes the literature using reports where outcome by specific pathologic pattern was indicated and standard definitions have been adhered to (the NSIP and "typical" patterns described by Gaxiola et al[43] are excluded because the authors indicated that they included cases with and without fibrosis in those categories). Four reports[27,32,33,43] indicated that CHP with a UIP pattern had a poor prognosis, with median survivals of 36 to 50 month, and Trahan et al[35] reported survivals of 9 months each for 2 patients whose biopsies showed only a UIP pattern. All those numbers were similar to the survival rates for UIP/IPF.

However, there are 2 outlier studies. Chiba et al[28] divided cases with a UIP pattern by the number of fibroblast foci per square centimeter and concluded that patients with fewer than 2.2 fibroblast foci/cm^2 did very well, with 70% survival at 100 months, whereas patients with more than 2.2 fibroblast foci/cm^2 had a median survival of 27 months. In a broad sense, that report is in accord with studies on UIP in which there was a survival difference by the number of fibroblast foci (eg, du Bois et al[48]), but those reports usually do not show the type of dramatic difference described by Chiba et al,[28] and other authors have found no effect of numbers of fibroblast foci on survival.[49,50] The 2.2 fibroblast foci/cm^2 (which was the median in the Chiba et al[28] study) was a very small number of fibroblast foci, and the patients with more than 2.2 fibroblast foci/cm^2 had a median survival of 27 months. Takemura et al[26] reported a remarkably good survival of 80% at 100 months for patient with CHPs with a UIP-like pattern, but they also recorded a median survival of 100 months for a comparison group of patients with UIP/IPF, a survival that is not typical of UIP/IPF. Both the Chiba et al[28] and Takemura et al[26] studies raise a question of whether there is a subgroup of patients with CHP and a UIP-like pattern that do relatively well, whereas for most patients with a UIP-like pattern, it carries a poor prognosis.

Churg et al[27] found that patients with a fibrotic NSIP pattern had exactly the same poor median survival (36 months) as patients with a UIP pattern had, and Ohtani et al[33] similarly reported identical median survivals (50 months) for fibrotic NSIP and UIP patterns; however, Wang et al[32] observed notionally better survival for patients with fibrotic NSIP pattern (median 108 months) compared with patients with a UIP pattern (median 40 months), but those values were not statistically different. Wang et al[32] also noted that the greater the amount of fibrosis in their fibrotic NSIP cases, the worse the prognosis. Nunes et al[51] reported a median survival of 50 months for patients with CHP and an NSIP picture, a survival which was, interestingly, considerably worse than that for idiopathic NSIP or NSIP associated with a connective tissue disease.

Only 2 reports describe the outcome in patients with purely peribronchiolar fibrosis: Churg et al[27] found a median survival of 144 months, but Wang et al[32] found a median survival of 60 months, only minimally (and not statistically) better than their patients with UIP patterns. Both those reports had few patients, so those conclusions may be tenuous, but it is hard to understand why pure centrilobular

Downloaded from https://aplm.kglmeridian.com at 2026-03-06 via free access

fibrosis, which is probably the earliest lesion of CHP, should lead to the same poor prognosis as a UIP picture.

CONCLUSIONS

In this review, we have attempted to summarize the pathology literature on CHP. None of the patterns described is absolutely pathognomonic of CHP. In particular, as noted above, with sufficiently severe fibrosis, the lobule tends to be overrun; for example, the lobule indicated by asterisk (*) in Figure 2, C, does have bridging fibrosis, but that lobule is almost completely overrun by fibrosis, and in our view, bridging fibrosis loses its specificity in that circumstance. The field shown in Figure 2, C, could be seen in either UIP/IPF or CHP with UIP-like pattern. At what point there is too much fibrosis to use bridging as a diagnostic separator is not clearly defined, and in some cases, the separation may be impossible. Similarly, peribronchiolar fibrosis and peribronchiolar fibroblast foci are typical of CHP when fibrosis is not too extensive, but with sufficient fibrosis in the lobule, those features may no longer be reliable separators. Sometimes those problems can be solved, even in very fibrotic cases, by finding foci of unequivocal subacute HP, but many cases do not have foci of subacute HP.

For these reasons, it is crucial to put the pathologic findings together with the clinical and imaging findings, particularly when the differential diagnosis is between UIP/IPF and CHP with a UIP-like pattern because in that circumstance, there is a difference in treatment. Predominantly upper zone disease, air-trapping, and more than minimal ground-glass opacities are high-resolution CT features that strongly favor CHP, rather than UIP/IPF. It is our policy not to sign out potential CHP cases without obtaining a detailed clinical history and having a discussion with the radiologist, preferably in the setting of a face-to-face, multidisciplinary discussion.

The exact pathologic pattern (beyond just fibrosis) on surgical lung biopsy in CHP probably correlates with prognosis. The available literature seems to indicate that CHP with a UIP pattern generally has a poorer prognosis, and the presence of numerous fibroblast foci in CHP with a UIP pattern suggests that it may be a self-perpetuating disease, as is true of UIP/IPF. However, as noted above, a few studies have cases with a UIP-like pattern and prolonged survival. Whether those cases reflect particular antigen exposures or patterns of exposure (eg, intermittent exposure to large amounts of antigen versus continuous exposure to small amounts of antigen[3]) is not known. These questions require studies with more cases to draw firm conclusions.

References

1. Salisbury ML, Myers JL, Belloli EA, Kazerooni EA, Martinez FJ, Flaherty KR. Diagnosis and treatment of fibrotic hypersensitivity pneumonia: where we stand and where we need to go [published online ahead of print December 21, 2016]. *Am J Respir Crit Care Med*. doi: 10.1164/rccm.201608-1675PP.
2. Walsh SL, Wells AU, Desai SR, et al. Multicentre evaluation of multidisciplinary team meeting agreement on diagnosis in diffuse parenchymal lung disease: a case-cohort study. *Lancet Respir Med*. 2016;4(7):557–565.
3. Ohtani Y, Saiki S, Sumi Y, et al. Clinical features of recurrent and insidious chronic bird fancier's lung. *Ann Allergy Asthma Immunol*. 2003;90(6):604–610.
4. Morell F, Villar A, Montero MÁ, Muñoz X, et al. Chronic hypersensitivity pneumonitis in patients diagnosed with idiopathic pulmonary fibrosis: a prospective case-cohort study. *Lancet Respir Med*. 2013;1(9):685–694.
5. Raghu G, Rochwerg B, Zhang Y, et al; American Thoracic Society; European Respiratory Society; Japanese Respiratory Society; Latin American Thoracic Association. An official ATS/ERS/JRS/ALAT clinical practice guideline: treatment of idiopathic pulmonary fibrosis—an update of the 2011 clinical practice guideline [published correction appears in *Am J Respir Crit Care Med*. 2015;192(5):644]. *Am J Respir Crit Care Med*. 2015;192(2):e3–19.
6. Rogliani P, Calzetta L, Cavalli F, Matera MG, Cazzola M. Pirfenidone, nintedanib and *N*-acetylcysteine for the treatment of idiopathic pulmonary fibrosis: a systematic review and meta-analysis. *Pulm Pharmacol Ther*. 2016;40(11):95–103.
7. Morisset J, Johannson KA, Vittinghoff E, et al. Use of mycophenolate mofetil or azathioprine for the management of chronic hypersensitivity pneumonitis [published online ahead of print November 2, 2016]. *Chest*. 2016;151(3):619–625. doi: 10.1016/j.chest.2016.10.029.
8. Fernández Pérez ER, Swigris JJ, et al. Identifying an inciting antigen is associated with improved survival in patients with chronic hypersensitivity pneumonitis. *Chest*. 2013;144(5):1644–1651.
9. Vourlekis JS, Schwarz MI, Cherniack RM, et al. The effect of pulmonary fibrosis on survival in patients with hypersensitivity pneumonitis. *Am J Med*. 2004;116(10):662–668.
10. Hanak V, Golbin JM, Hartman TE, Ryu JH. High-resolution CT findings of parenchymal fibrosis correlate with prognosis in hypersensitivity pneumonitis. *Chest*. 134(1):133–1338.
11. Kern RM, Singer JP, Koth L, et al. Lung transplantation for hypersensitivity pneumonitis. *Chest*. 2015;147(6):1558–1565.
12. Silva CI, Müller NL, Lynch DA, et al. Chronic hypersensitivity pneumonitis: differentiation from idiopathic pulmonary fibrosis and nonspecific interstitial pneumonia by using thin-section CT. *Radiology*. 2008;246(1):288–297.
13. Spagnolo P, Rossi G, Cavazza A, et al. Hypersensitivity pneumonitis: a comprehensive review. *J Investig Allergol Clin Immunol*. 2015;25(4):237–250;
14. Lacasse Y, Selman M, Costabel U, et al; HP Study Group. Classification of hypersensitivity pneumonitis: a hypothesis. *Int Arch Allergy Immunol*. 2009;149(2):161–166.
15. Adler BD, Padley SP, Müller NL, Remy-Jardin M, Remy J. Chronic hypersensitivity pneumonitis: high resolution CT and radiographic features in 16 patients. *Radiology*. 1992;185(1):91–95.
16. Hansell DM, Wells AU, Padley SP, Müeller NL. Hypersensitivity pneumonitis: correlation of individual CT patterns with functional abnormalities. *Radiology*. 1996;199(1):123–128.
17. Lynch DA, Rose CS, Way D, King TE Jr. Hypersensitivity pneumonitis: sensitivity of high resolution CT in a population-based study. *AJR Am J Roentgenol*. 1992;159(3);469–472.
18. Lynch DA, Newell JD, Logan PM, King TE Jr, Müller NL. Can CT distinguish hypersensitivity pneumonitis from idiopathic pulmonary fibrosis? *AJR Am J Roentgenol*. 1995;165(4):807–811.
19. Silva CI, Churg A, Müller NL. Hypersensitivity pneumonitis: spectrum of high-resolution CT and pathologic findings. *AJR Am J Roentgenol*. 2007;188(2):334–344.
20. Small JH, Flower CD, Traill ZC, Gleeson FV. Air-trapping in extrinsic allergic alveolitis on computed tomography. *Clin Radiol*. 1996;51(10):684–688.
21. Buschman DL, Gamsu G, Waldron JA Jr, Klein JS, King TE Jr. Chronic hypersensitivity pneumonitis: use of CT in diagnosis. *AJR Am J Roentgenol*. 1992;159(5):957–960.
22. Churg A, Müller NL. Hypersensitivity pneumonitis. In: Churg A, Müller NL, eds. *Atlas of Interstitial Lung Disease Pathology: Pathology With High Resolution CT Correlations*. Philadelphia, PA: Lippincott Williams Wilkins; 2013:95–110.
23. Herbst JB, Myers JL. Hypersensitivity pneumonia: role of surgical lung biopsy. *Arch Pathol Lab Med*. 2012;136(8):889–895.
24. Castonguay MC, Ryu JH, Yi ES, Tazelaar HD. Granulomas and giant cells in hypersensitivity pneumonitis. *Hum Pathol*. 2015;46(4):607–613.
25. Churg A, Muller NL, Flint J, Wright JL. Chronic hypersensitivity pneumonitis. *Am J Surg Pathol*. 2006;30(2):201–208.
26. Takemura T, Akashi T, Kamiya H, et al. Pathological differentiation of chronic hypersensitivity pneumonitis from idiopathic pulmonary fibrosis/usual interstitial pneumonia. *Histopathology*. 2012;61(6):1026–1035.
27. Churg A, Sin DD, Everett D, Brown K, Cool C. Pathologic patterns and survival in chronic hypersensitivity pneumonitis. *Am J Surg Pathol*. 2009;33(12):1765–1770.
28. Chiba S, Tsuchiya K, Akashi T, et al. Chronic hypersensitivity pneumonitis with a usual interstitial pneumonia-like pattern: correlation between histopathologic and clinical findings. *Chest*. 2016;149(6):1473–1481.
29. Myers JL. Hypersensitivity pneumonia: the role of lung biopsy in diagnosis and management. *Mod Pathol*. 2012;25(suppl 1):S58–S67.
30. Takemura T, Akashi T, Ohtani Y, Inase N, Yoshizawa Y. Pathology of hypersensitivity pneumonitis. *Curr Opin Pulm Med*. 2008;14(5):440–454.
31. Akashi T, Takemura T, Ando N, et al. Histopathologic analysis of sixteen autopsy cases of chronic hypersensitivity pneumonitis and comparison with idiopathic pulmonary fibrosis/usual interstitial pneumonia. *Am J Clin Pathol*. 2009;131(3):405–415.
32. Wang P, Jones KD, Urisman A, et al. Pathological findings and prognosis in a large prospective cohort of chronic hypersensitivity pneumonitis [published online ahead of print February 18, 2017]. *Chest*. doi:10.1016/j.chest.2017.02.011.
33. Ohtani Y, Saiki S, Kitaichi M, et al. Chronic bird fancier's lung: histopathological and clinical correlation: an application of the 2002 ATS/ERS consensus classification of the idiopathic interstitial pneumonias. *Thorax*. 2005;60(8):665–671.
34. Fukuoka J, Franks TJ, Colby TV, et al. Peribronchiolar metaplasia: a common histologic lesion in diffuse lung disease and a rare cause of interstitial lung disease: clinicopathologic features of 15 cases. *Am J Surg Pathol*. 2005;29(7):948–954.

Downloaded from https://aplm.kglmeridian.com at 2026-03-06 via free access

35. Trahan S, Hanak V, Ryu JH, Myers JL. Role of surgical lung biopsy in separating chronic hypersensitivity pneumonia from usual interstitial pneumonia/idiopathic pulmonary fibrosis: analysis of 31 biopsies from 15 patients. *Chest*. 2008;134(1):126–132.
36. Hashisako M, Tanaka T, Terasaki Y, et al. Interobserver agreement of usual interstitial pneumonia diagnosis correlated with patient outcome. *Arch Pathol Lab Med*. 2016;140(12):1375–1382.
37. Churg A, Wright JL, Tazelaar HD. Acute exacerbations of fibrotic interstitial lung disease. *Histopathology*. 2011;58(4):525–530.
38. Selman M, Pardo A, Barrera L, et al. Gene expression profiles distinguish idiopathic pulmonary fibrosis from hypersensitivity pneumonitis. *Am J Respir Crit Care Med*. 2006;173(2):188–198.
39. Kim SY, Diggans J, Pankratz D, et al. Classification of usual interstitial pneumonia in patients with interstitial lung disease: assessment of a machine learning approach using high-dimensional transcriptional data. *Lancet Respir Med*. 2015;3(6):473–482.
40. Yousem SA, Dacic S. Idiopathic bronchiolocentric interstitial pneumonia. *Mod Pathol*. 2002;15(11):1148–1153.
41. Churg A, Myers J, Suarez T, et al. Airway-centered interstitial fibrosis: a distinct form of aggressive diffuse lung disease. *Am J Surg Pathol*. 2004;28(1):62–68.
42. Fenton ME, Cockcroft DW, Wright JL, Churg A. Hypersensitivity pneumonitis as a cause of airway-centered interstitial fibrosis. *Ann Allergy Asthma Immunol*. 2007;99(5):465–456.
43. Gaxiola M, Buendía-Roldán I, Mejía M, et al. Morphologic diversity of chronic pigeon breeder's disease: clinical features and survival. *Respir Med*. 2011;105(4):608–614.
44. Kuranishi LT, Leslie KO, Ferreira RG, et al. Airway-centered interstitial fibrosis: etiology, clinical findings and prognosis. *Respir Res*. 2015;16:55.
45. Cardasis JJ, MacMahon H, Husain AN. The spectrum of lung disease due to chronic occult aspiration. *Ann Am Thorac Soc*. 2014;11(6):865–873.
46. Hu X, Yi ES, Ryu JH. Diffuse aspiration bronchiolitis: analysis of 20 consecutive patients. *J Bras Pneumol*. 2015;41(2):161–166.
47. Walsh SL, Sverzellati N, Devaraj A, Wells AU, Hansell DM. Chronic hypersensitivity pneumonitis: high resolution computed tomography patterns and pulmonary function indices as prognostic determinants. *Eur Radiol*. 2012;22(8):1672–1679.
48. du Bois RM. Fibroblastic foci: time to be counted [comment]? *Chest*. 2006;130(1):3–5.
49. Flaherty KR, Colby TV, Travis WD, et al. Fibroblastic foci in usual interstitial pneumonia: idiopathic versus collagen vascular disease. *Am J Respir Crit Care Med*. 2003;167(10):1410–1415.
50. Collard HR, Cool CD, Leslie KO, Curran-Everett D, Groshong S, Brown KK. Organizing pneumonia and lymphoplasmacytic inflammation predict treatment response in idiopathic pulmonary fibrosis. *Histopathology*. 2007;50(2):258–265.
51. Nunes H, Schubel K, Piver D, et al. Nonspecific interstitial pneumonia: survival is influenced by the underlying cause. *Eur Respir J*. 2015;45(3):746–755.

Downloaded from https://aplm.kglmeridian.com at 2026-03-06 via free access

Prepare Submissions Now for the CAP18 Abstract Program

Abstract and case study submissions to the College of American Pathologists (CAP) 2018 Abstract Program will be accepted beginning at noon Monday, January 8 through 5 p.m. Central time Friday, March 9, 2018.

Accepted submissions will appear on the *Archives of Pathology & Laboratory Medicine* Web site as a Web-only supplement to the September 2018 issue. Awards will be presented to the winners of the Top 5 Junior Member Abstract Program.

The CAP18 meeting will be held October 20–24 in Chicago. Visit the CAP18 Web site (www.cap.org/cap18) and the *Archives* Web site (www.archivesofpathology.org) for additional abstract program information as it becomes available.